

CASE STUDY

- 100% WOUND REDUCTION IN 14 WEEKS
- 4 ACTIGRAFT APPLICATIONS

PATIENT:

79 Year Old, Female

PAST MEDICAL HISTORY:

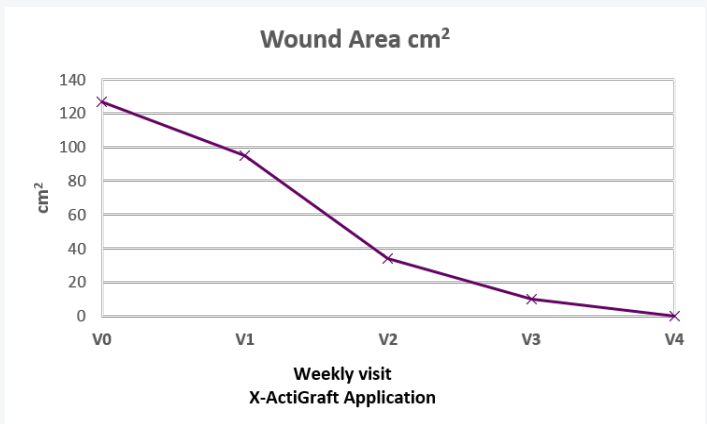
Chronic Venous Insufficiency, Hypertension, Anemia, Osteoporosis, Hyponatremia, Polymyalgia, Rheumatica, Colostomy, Diverticulosis Colon, Rheumatoid Arthritis treated with steroids for 40 and with Methotrexate (chemotherapy for Rheumatoid Arthritis)

WOUND HISTORY:

- 1 month old VLU with exposed bone

PAST TREATMENTS:

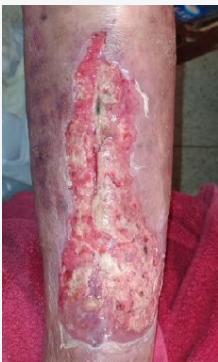Polidin, AQUACEL, Flaminol



V=Weekly Application

ACTIGRAFT TREATMENT PROGRESSION:

Week 1



Week 14

